

---

**2019.2**

**South Australia  
&  
Northern Territory  
Trial SAQ Exam**

**Booklet 1**

**SAQs 1 – 9**

---

## SAQ 1 (13 marks)

You are the ED consultant on an evening shift and your resident presents the following patient to you:

“Mrs. Smith is an 86-year-old female who fell at home today. She tripped over a rug in her lounge room and landed on her left side. She is complaining of pain in her left hip and groin.”

a) Apart from pelvic and proximal femur fractures, list three (3) other frailty fractures you need to consider (3 marks)

- C-spine eg dens fracture
- Forearm eg Colles fracture
- Thoracolumbar eg crush fracture

b) List two (2) physical examination findings for each of the following fractures which may help differentiate it from other injuries. (6 marks)

Injury	Two (2) Physical examination findings
Intertrochanteric neck of femur fracture	<ul style="list-style-type: none"> <li>• Shortened and externally rotated,</li> <li>• painful axial compression,</li> <li>• usually unable to straight leg raise,</li> <li>• usually unable to weight bear</li> </ul>
Greater trochanter fracture	<ul style="list-style-type: none"> <li>• Tender laterally over greater trochanter,</li> <li>• less commonly painful to axial compression,</li> <li>• weight bearing usually preserved</li> </ul>
Pubic rami fracture	<ul style="list-style-type: none"> <li>• Tender medial to hip joint,</li> <li>• less painful on axial compression,</li> <li>• pain on pelvic compression,</li> <li>• may be able to weight bear</li> </ul>

- c) Describe the findings on the pelvic x-ray (**see image in props booklet**) (1 mark)
- Undisplaced left superior and minimally displaced inferior pubic rami fractures
- d) Describe the treatment of this injury (2 marks)
- Conservative, analgesia, weight bear as tolerated
- e) What is the likely disposition of this patient (1 mark)
- General medicine or geriatrics
  - Respite or Rehab also acceptable – if medically well, pain controlled with analgesia, bed available

---

**SAQ 2 (15 marks)**

A 30y old male, presents to your ED with a productive cough, fever, shortness of breath and haemoptysis. He has a history of IV drug use but no other significant past medical history.

His observations are temperature 38.6, respiratory rate 30, saturating 91% on room air, pulse 140bpm (sinus rhythm) and BP 90/55

a) Please list three (3) of the most important abnormalities on his chest X. **(see image in props booklet)** (3 marks)

- **Right mid zone cavitating lesion**
- Right lower/middle lobe pneumonia
- Air bronchogram
- Tiny right pleural effusion
- Fluid in horizontal fissure
- Horizontal line crossing mediastinum (? artefact)
  
- Need cavitating lesion and 2 others if not maximum one mark

b) Please list the three (3) most common infectious organisms and two (2) non-infectious causes that could produce a similar appearance on chest X-ray (5 marks)

- Need bolded answers for full marks
- Infectious
  - **Staph aureus**
  - **Mycoplasma/TB**
  - Anerobes (Peptostreptococcus/ Fusobacterium nucleatum/ Prevotella)
  - Gram negative Klebsiella/legionella/pseudomonas/e.coli/proteus/H.influenzae
  - Strep pneumoniae
  - Fungal Aspergillosis/cryptococcosis/invasive candiditis
  - Parasites Echinococcus/ Pneumocystis J. (PJP)
- Non-infectious
  - **Malignancy** (primary/metastatic/lymphoma)

- Vascular (Pulmonary infarction/thromboembolic)
- Granulomas (RA, sarcoidosis, Wegener’s)
- Other Pneumoconiosis/bronchiectasis/lucite plombage
- Congenital/cyst

c) List and justify the four (4) most important investigations that may assist in establishing a diagnosis (4 marks)

Investigation	Justification
<b>1 Sputum analysis for acid fast bacilli (antigen or culture)</b>	<ul style="list-style-type: none"> <li>• <b>Confirm diagnosis of TB</b></li> </ul>
2 CT chest	<ul style="list-style-type: none"> <li>• To detect cavitation or infarction, identification of smaller lesions not seen on CXR</li> </ul>
3 Echocardiogram	<ul style="list-style-type: none"> <li>• Identify IE in IV drug user</li> </ul>
4 Blood cultures	<ul style="list-style-type: none"> <li>• Help rationalise antibiotics/IE</li> </ul>

- Need bold for full marks

d) Briefly outline three (3) of the most important initial treatments you would institute in this patient (3 marks).

- **Broad spectrum antibiotics (must have Staph Aureus cover)**
- **Oxygen with saturation end point 94% or above**
- **IV fluid resuscitation 15-30mls/kg**
- Inotropes (NA) for a MAP >65
- Respiratory support if deterioration (invasive)
- Disposition (Respiratory/medical/ICU)

- Need bold for full marks

---

### SAQ 3 (12 marks)

You are undertaking a locum shift in a regional emergency department. A 63-year-old male has presented reporting recurrent chest pains for the past week. The pain was initially intermittent, but became constant after eating dinner last night, roughly 12 hours ago. He has a history of gout, takes allopurinol and has no allergies. He has been placed in the resus bay and been connected to cardiac monitoring. His ECG is shown **in the props booklet**.

a) Please describe and interpret the ECG (**see image in props booklet**) (4 Marks)

- Inferior STE - marginal for meeting the criteria for STEMI
- ST depression in V2 and/or aVL may represent posterior or RV involvement
- 1mm STE in lateral leads indicates probable lateral involvement
- Q waves indicate evidence of infarct more than a few hours old OR acute infarction and previous old inferolateral MI
- Borderline upright T wave in V1 suggestive of ischaemia

b) List four (4) additional investigations that might clarify the extent of the patient's problem and explain how they may help to do so. (4 marks)

- Cardiac biomarkers Troponins +/- CKMB – pattern of elevation will indicate whether MI acute or recent
- Echocardiography – may show features of RV or posterior hypokinesis (as well as inferior)
- RV and posterior ECG leads – may indicate features of RV or posterior involvement.
- CXR – showing pulmonary congestion/pleural effusions suggests significant myocardial dysfunction

c) List four (4) medications (with routes of administration and doses) you will prioritise in your management of this patient. (4 Marks)

- Aspirin 300mg orally
- 2nd anti-platelet agent: Ticagrelor 180, Prasugrel 60mg or Clopidogrel 300mg orally

- Enoxaparin 1mg/kg SC BD or Unfractionated IV heparin 60-70 units/kg bolus and 12-15 units/kg/hour aiming for aPTT 1.5-2.5 x control. (Other reasonable doses are acceptable)
- Cautious GTN (either SL or infusion with appropriate doses) avoiding hypotension, titrated to reduce pain
- Titrated opioid analgesia (with reasonable doses), if other therapies fail or patient severely distressed by the pain.

References:

National Heart Foundation of Australia & Cardiac Society of Australia and New Zealand: Australian Clinical Guidelines for the Management of Acute Coronary Syndromes 2016

**SAQ 4 (24 marks)**

You are attending a vehicle accident on a busy highway. A 4-wheel-drive has collided with a truck carrying hazardous material. There are fire, state emergency service and ambulance crews in attendance. There are a number of casualties.

a) With regards to management of mass casualty situations, what are the seven (7) key elements of the on-scene management of a major incident response? (7 marks)

- Command and Control
- Safety – self, scene, survivors
- Communication
- Assessment
- Triage
- Treatment
- Transport

The fire officer in charge of the scene is waiting to give you a METHANE report to update you on the current situation.

b) Outline the meaning of the disaster communication acronym METHANE (7 marks)

- **M**y call sign/ major incident declared
- **E**xact Location of incident
- **T**ype of incident with brief details
- **H**azards present and potential
- **A**ccess routes to the incident
- **A**pproximate number and nature of casualties
- **E**mergency services present and required



- c) What are the two (2) types of on-scene major incident triage that occur in a mass casualty situation, and what does the result of each triage determine? (4 Marks)

<b>Triage Type</b>	<b>Determines what?</b>
<ul style="list-style-type: none"> <li>• Sieve/ Primary triage</li> </ul>	<ul style="list-style-type: none"> <li>• priorities for urgency of patient treatment</li> </ul>
<ul style="list-style-type: none"> <li>• Sort/ Secondary triage</li> </ul>	<ul style="list-style-type: none"> <li>• priorities for urgency of patient transport</li> </ul>

- d) Your initial survey of the scene reveals that all but one of the 5 patients are walking wounded. The last patient is trapped in the 4WD by his legs. He is screaming in pain with an obvious open humeral shaft fracture. BP 60/30, P160, Sats 80%, RR 46 with reduced AE right chest, GCS 15 and a patent airway. It is estimated that it will take 20 minutes to free him safely. You have access to both arms and his torso and airway. List 6 (six) immediate management steps you will take. (6 Marks)

- Application of oxygen via mask – aiming to increase Sats to >95%
- Decompression R chest with needle thoracostomy – to be followed by definitive management when extricated
- Large bore IV access
- Blood/ fluid resuscitation – aiming for MAP 60 initially – for reassessment to determine end points when extricated and determination of presence of head injury or not.
- Intravenous analgesia to facilitate rapid extrication and manage distress
- Dress and splint humeral fracture
- Application of pelvic binder to limit haemorrhagic loss within pelvis
- Preparation for management of patient post extrication – likely intubation and ventilation, insertion of ICC/ finger thoracostomy, further IV access/ sedation and analgesia, immobilisation of spine, communication to receiving facility re: injuries

---

## SAQ 5 (12 marks)

An 18 year old man presents with a 2-week history of general malaise, myalgia and fever. He reports that he was given a course of antibiotics by his GP two weeks ago for a cough, but has continued to feel unwell despite completing the course. He presents today worried about a painful rash involving his skin and mouth that has rapidly developed over the past 24 hours.

a) List the three (3) MOST IMPORTANT differential diagnoses for this rash. (see image in props booklet) (3 marks)

- **Toxic epidermal necrolysis**
- Stevens-Johnson syndrome
- **Staphylococcal scalded skin syndrome**
- Erythema multiforme
- Pemphigus / pemphigoid
- Possibly also include: DRESS, acute generalized exanthematous pustulosis, erythroderma

b) What are the four (4) of the most common causes of this disease? ( 4 marks )

- Medication
  - Allopurinol
  - Anticonvulsants – carbamazepine, lamotrigine, phenytoin, phenobarbitone
  - Antibiotics - Sulfonamide AB's Beta-lactams
  - Nevirapine
  - Omeprazole
  - Analgesics – paracetamol, NSAIDs - mostly 'oxicams'
  - Dapsone
- Infections
  - Mycoplasma Pneumonia
  - Cytomegalo virus

c) Name two (2) risk factors for this disease ( 2 marks )

- HIV/AIDS
- Systemic Lupus Erythema
- Malignancies
  - Lymphoma
  - Leukaemia

d) List three (3) important treatments for this patient, irrespective of the cause of the rash ( 3 marks )

- IV fluid and electrolyte management
- Barrier nursing
- Temperature control
- Analgesia
- Skin covering

## SAQ 6 (12 marks)

You are the ED Consultant leading the Trauma team in a Major Trauma Centre.

A 32 year old, previously healthy male has been brought in following a high-speed motor-bike crash which occurred approximately 90 minutes ago. His scene GCS was initially 13, E3 V4 M6, then declined to 7, E1 V2 M4, and he was subsequently intubated. The patient has had bilateral finger thoracostomies and given 2 units of PRBC by the pre-hospital retrieval service.

The initial primary survey in the resus room reveals

A – ETT at 22cm at the teeth.

B – Sats 96% on FiO2 100%, PEEP 5, ETCO2 47, TV 500, Rate 12, PIP 20

C – BP 110 / 60 mmHg, MAP 77, PR 117

D – E1 VT M1, Pupils 4mm, equal and reactive

E – Temp 35.7, right sided scalp and facial lacerations. Bruising to right flank. Pelvic binder in-situ. Patient weight approximately 80kg. Sedated on propofol 1% infusion at 10mls per hour with intermittent fentanyl, last being 40mcg 10 minutes before arrival in resus.

There has been a CXR, PXR, eFAST performed. **(see images in props booklet)**

- a) List three (3) different life-threatening injuries present in this patient and the basis for your diagnoses (6 marks)

Injury	Basis for diagnosis
Intra-abdominal injury with free intraperitoneal fluid	Strongly positive FAST scan demonstrating free fluid in Morrisons pouch
Traumatic brain injury with intra-cranial haemorrhage	Decrease in GCS from 13 to 7
Major pelvic fracture with likely bleeding	Displaced superior pubic ramus/acetabular fracture and inferior pubic ramus fracture (need all for 1 mark)

VBG results are

pH	7.18	
HCO <sub>3</sub>	20	mmol/L
pCO <sub>2</sub>	57	mmHg
pO <sub>2</sub>	83	mmHg
Lactate	3.2	mmol/L (n < 2)
Ion Ca.	0.87	mmol/L (n 1.1 – 1.3)
Na	138	mmol/L (n 135-145)

b) On the basis of his VBG, what medication and dose should you administer immediately? (1 mark)

- Calcium Chloride or Gluconate 10mls, 10%, IV

c) What would be your ventilation strategy and aim? (2 marks)

- Increase ventilation to aim for ETCO<sub>2</sub> low 30's given difference in ETCO<sub>2</sub> and PCO<sub>2</sub> in a patient with suspected traumatic brain injury – 560ml x 16 bpm or similar

d) What blood pressure goals will you have for this patient and state your reasoning? (2 marks)

- Aim - SBP > 100-110 or MAP > 80
- Reasoning – Acknowledgement that hypotension will contribute to secondary brain injury and increase mortality. This takes priority over permissive hypotension

His current observations haven't changed in the first 20 minutes in the resus bay but his right pupil is now 7mm and un-reactive.

e) State one (1) treatment and dose you would give (1 mark)

- NaCl 3% 3mls per kg aim Na <155. Or appropriate dose of 6%, 7.5% NaCl
- Accept mannitol 0.5-1gm / kg 20% solution

**SAQ 7 (14 marks)**

A 16-year-old boy is brought into the ED by his parents with a complaint of fever and fatigue for six days. Further questioning reveals that he has had some weight loss and has noticed a firm non-painful lump in the left lateral side of his neck. He denies any cough, difficulty breathing, gastrointestinal, or urinary symptoms.

Vital signs are: Pulse 110, BP 108/62 mmHg, RR 18, sats 98% on room air, T 39.2 Celsius

a) List your three (3) top differential diagnoses (3 marks)

- **Hodgkins lymphoma and/or non-Hodgkins lymphoma**
- **EBV infection/glandular fever/infectious mononucleosis**
- **Bacterial tonsillitis (not viral)**
- Hyperthyroidism with thyroid mass
- Leukemia
- Other bacterial infection with nodular reaction

b) List the three (3) most important additional historical features you would seek to help establish a diagnosis and explain how each may be of use. (3 marks)

- Sore throat – suggest tonsillitis
- Dysphagia – suggests oropharyngeal pathology
- Night sweats – suggests lymphoma
- Features of infection in the regional drainage area of the node
- History suggestive of TB
- History of potential HIV exposure
- Back, chest pain or abdominal pain, shortness of breath – suggests more generalised nodal involvement
- Easy bruising – suggests leukaemia
- Features of hyper or hypothyroidism

List the three (3) most important physical examination findings you would look for to help establish a diagnosis and explain how each may be of use (3 marks)

Any of the following is acceptable with 0.5 marks for each correct answer:

- Features of tonsillitis or mass – bacterial infection or malignancy
- Other lymphadenopathy (neck, axilla, and groin; hepatosplenomegaly) – suggests lymphoma
- Signs of anaemia or thrombocytopaenia (petechiae, purpura, bruising) – suggests leukaemia
- Establishing size, location and mobility of the lump – large, matted fixed masses are usually malignant
- Features of infection or malignancy in the drainage area of the node(s) involved.
- Examination of thyroid – mass suggests thyroid malignancy
- Features of pleural effusion – suggest malignant process

c) Describe five (5) investigations that might be most helpful in diagnosing this boy's illness, and explain how each may be of use (5 marks)

- **CBE: may be normal or show anaemia, low wbc, high wbc, thrombocytopaenia**
- LDH may be high if this is a lymphoma
- LFT's likely normal but may be elevated in EBV (or similar) infection
- **Chest x-ray to look for signs of infection or mediastinal nodes**
- Ultrasound of neck mass
- **Needle biopsy of neck mass**
- CT of chest and abdomen to look for other nodes
- ESR and CRP may be elevated in infection or with a lymphoma
- **Cultures (throat, other local lesions, blood) for bacterial infection**
- Viral serology for EBV, CMV, HIV

**SAQ 8 (14 marks)**

An 18-month-old boy presents with fever for 48 hours on a background of being non-specifically unwell for several weeks. His parents are concerned that he has been coughing for 'several months' and is 'never healthy'.

His parents report he was a term baby 3.5kg with no complications and appeared well until breast feeding was ceased at around 5 months of age when his mother returned to work, since then he has had several 'chest infections'. He is fully immunised. His GP has prescribed a course of antibiotics on 3 separate occasions. He was admitted overnight to hospital 4 months ago with a right sided pneumonia.

His observations are below:

Temp	38.2 C
HR	120 bpm
RR	42 /min
BP	88/50 mmHg
SpO2	95% on room air

On examination: right sided crackles, chesty wet cough, eating and drinking well and not dehydrated. Playful and running around.

- a) His CXR is shown (**see image in props booklet**). Provide your interpretation (1 mark)
- Right middle lobe pneumonia



- b) Outline appropriate antibiotic choice, dose and frequency for an 18-month-old child with mild pneumonia. Include antibiotic choice for penicillin allergic (severe anaphylaxis) and non-allergic child. Use the table below (4 marks)

	<b>Antibiotic</b>	<b>Dose and frequency</b>
<b>No allergies</b>	<ul style="list-style-type: none"> <li>• Amoxycillin</li> </ul>	<ul style="list-style-type: none"> <li>• 25mg/kg tds</li> </ul>
<b>Severe penicillin allergy</b>	<ul style="list-style-type: none"> <li>• Azithromycin</li> <li>• Clarithromycin</li> </ul>	<ul style="list-style-type: none"> <li>• 10mg/kg daily</li> <li>• 7.5mg/kg bd</li> </ul>

- c) What is the recommended duration of oral antibiotic therapy in mild paediatric pneumonia (1 mark)
- 3 – 5 days
- d) Give four (4) possible explanations for this child's recurrent illnesses (4 marks)
- Recurrent bacterial pneumonia
  - Bronchiectasis
  - Inhaled foreign body
  - Cystic fibrosis
  - Immune deficiency
- e) Outline your preferred disposition of this patient and justify? (1 mark)
- Home with handout re pneumonia – because he is well and tolerating oral intake does not need admission but does require follow up as below
  - Could accept admission if social concerns/ family live long distance or concerns of loss to follow up

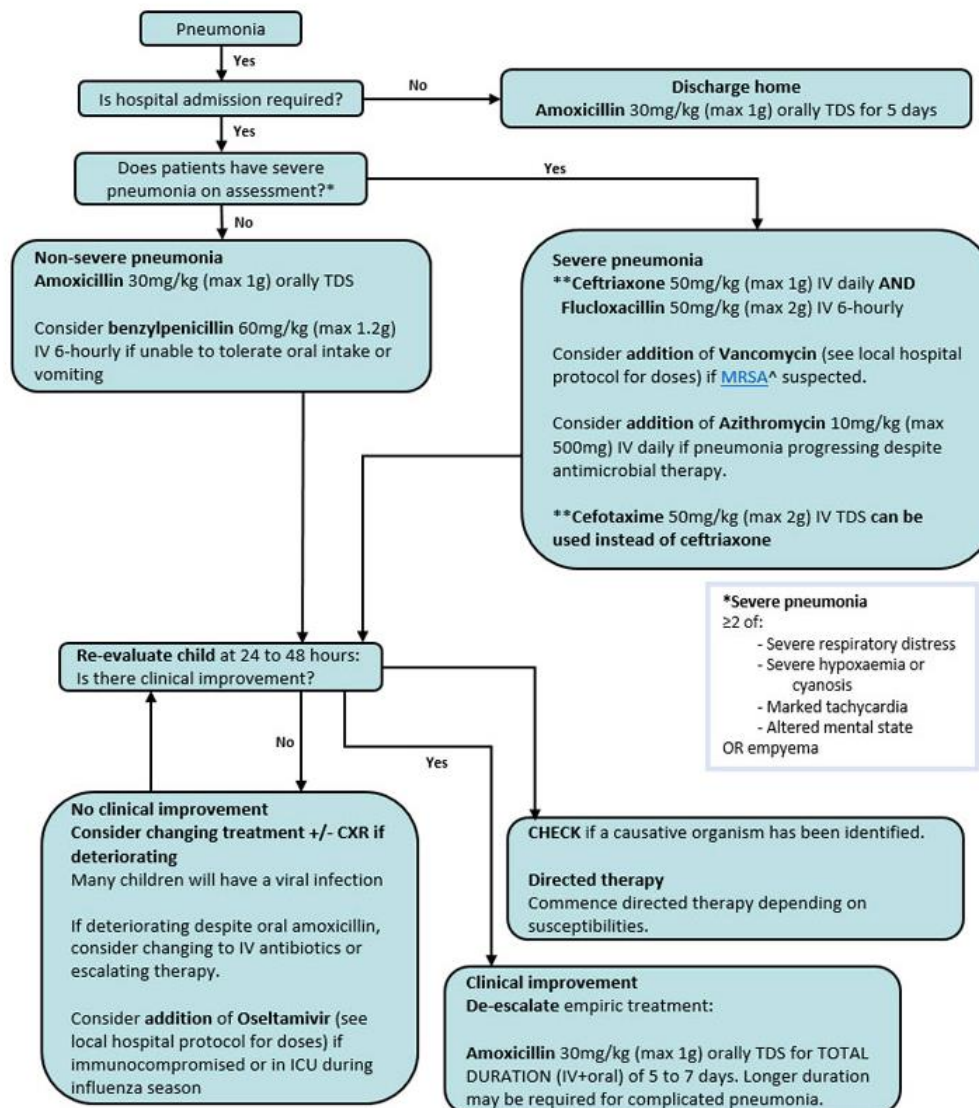
f) List three (3) follow up investigations that would be appropriate to help determine the cause for his recurrent infections (3 marks)

- FBC
- Immunoglobulins
- CT chest
- Bronchoscopy
- Sweat test

**Model answer supporting documents/links/information**

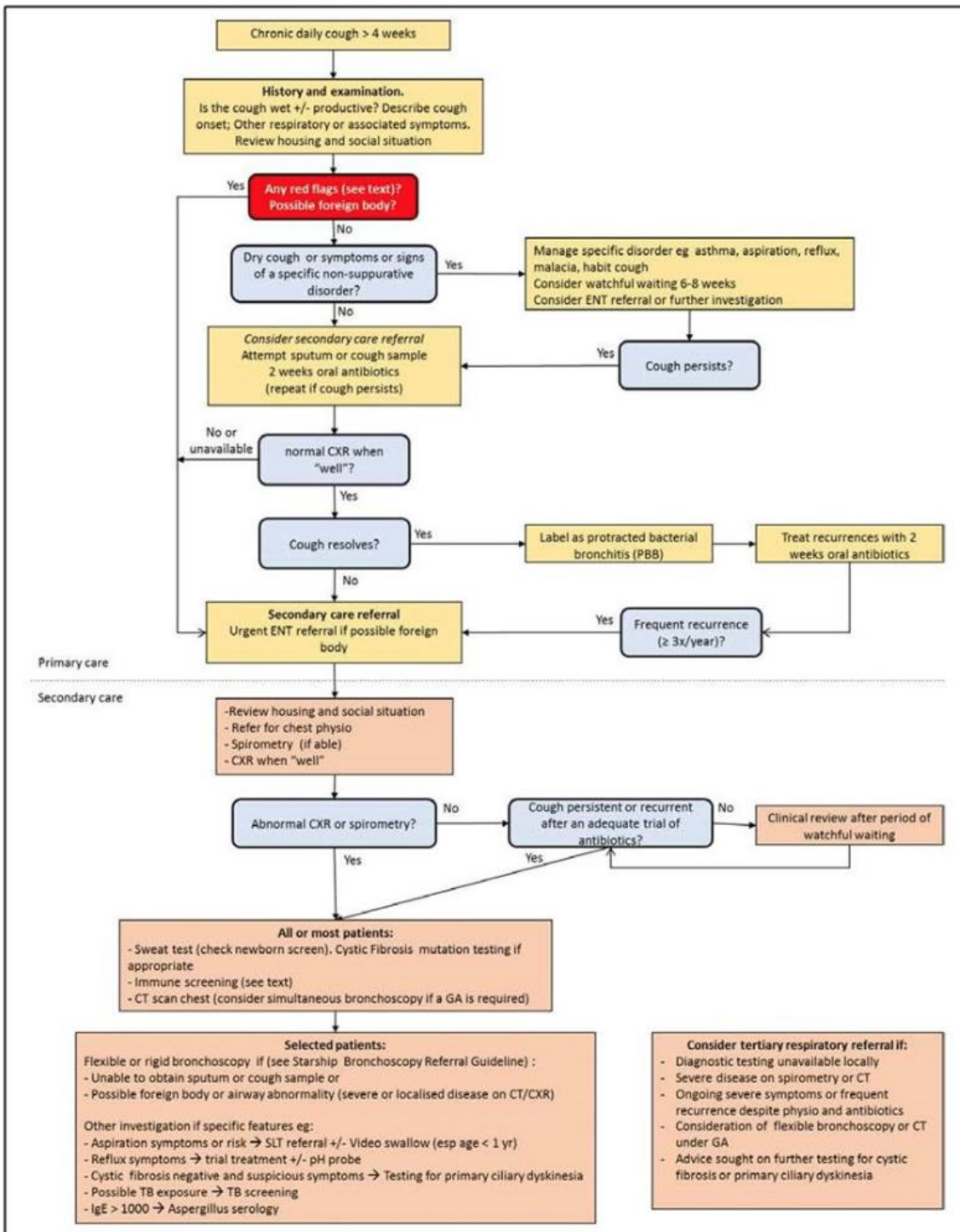
- <https://www.starship.org.nz/guidelines/cough/>
- [https://www.rch.org.au/clinicalguide/guideline\\_index/Community\\_acquired\\_pneumonia/](https://www.rch.org.au/clinicalguide/guideline_index/Community_acquired_pneumonia/)

### Antibiotic Management



### Penicillin hypersensitivity

- Please refer to the [Therapeutic Guidelines](#) for suggested management of patients reporting hypersensitivity to penicillin.
- Non-beta-lactam antibiotic alternatives include:
  - Azithromycin 10mg/kg (max 500mg) orally daily *instead of oral amoxicillin*
  - Vancomycin IV (see local hospital protocol for doses) *instead of benzylpenicillin or cefotaxime/ceftriaxone.*

**Red flags include:**

- Neonatal onset of cough
- Coughing or choking during feeding
- Stridor
- Sudden onset of cough or a history of choking (possible foreign body)
- Systemic signs or symptoms (shortness of breath, hypoxia or cyanosis, night sweats, weight loss, haemoptysis)
- Signs of chronic disease (clubbing, poor growth, chest wall deformity)

### SAQ 9 (14 marks)

A 5-year-old child is brought to ED after an unwitnessed fall in a playground at school, complaining to her parents about a 'sore' and swollen elbow when they picked her up. Her reception classmates say that she may have fallen from monkey bars. She has a pain score of 7/10 and points to her left elbow as the site of pain. The elbow is swollen, with localised bruising anteriorly and no open wounds. She is reluctant to fully flex the elbow and is neurovascularly intact distally.

X-rays of her elbow as ordered by the triage nurse are seen below (**and in the props booklet**).

a) Please describe five (5) of the most important findings on X-ray (**see images in the props booklet**). These may be positive or negative findings. (5 marks)

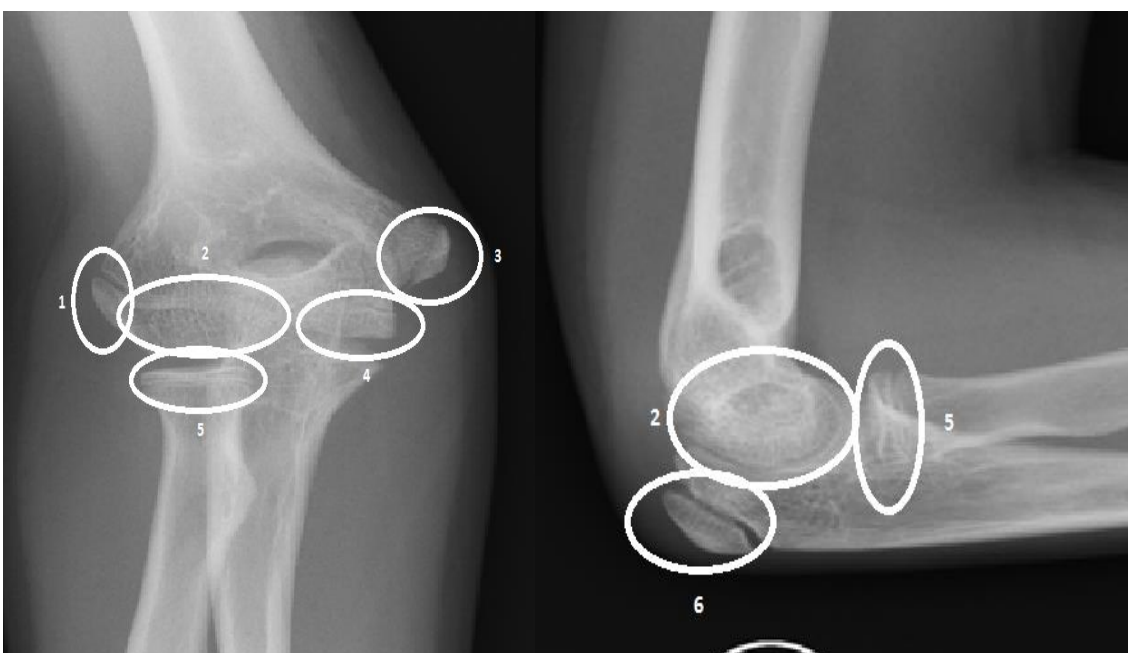- **Lateral CONDYLAR (not EPI-condyle) fracture of the distal humerus. (Half mark for "epicondylar fracture")**
- **1-2mm displacement (acceptable range 1-3mm)**
- Large anterior fat pad sign
- Large posterior fat pad sign
- Prominent soft tissue swelling laterally
- Radiocapitellar and ulnar trochlear line is maintained on the AP film
- Radiocapitellar line maintained on lateral film.
- Elbow joint enlocated
- Absent gas in tissue to suggest open fracture
- Additional Points:
  - Three views provided are AP, Lat and Oblique (the latter showing the fractured segment most clearly with a distance of 2mm separation)

b) Outline the specific management of this injury (3 marks)

- Adequate description of either initially conservative or operative management are acceptable.
- **Undisplaced fractures** are treated with a long arm cast (**2 marks**) (collar and cuff/sling not acceptable)

- i.e. an Above Elbow POP backslab in ED with orthopaedic review and fracture clinic follow-up arranged with 7 to 10 days (1 mark) (planned review essential)
- Since these fractures are intra-articular they are prone to nonunion because the fracture is bathed in synovial fluid.
- These fractures must be carefully monitored as they have a tendency to displace. At follow up both AP and Oblique views are taken after removal of the cast.
- **Displaced fractures**, or where there are concerns re. neurovascular compromise, prompt orthopaedic review is required.
  - Classically, >2mm of displacement on any of the three views should be considered unstable and surgical fixation of the fracture warranted. Once displaced fractures consolidate in a malunited position, treatment is difficult and fraught with complications.
  - For this reason surgical reduction is recommended within the first 48 hours. Open reduction is indicated for all displaced fractures and those demonstrating joint instability

c) Using the numbers for each of the ossification centres around the elbow in the images below (**also available in the props book**), list (in chronological order from first to last), each ossification centre in the table that follows. Also name the ossification centre associated with each number and the age each ossification centre is normally visible on radiography (6 marks)



<b>Number of ossification centre</b> (in order of appearance from first to last)	<b>Name of ossification centre</b>	<b>Age first visible</b>
2	Capitellum	1 to 2yr
5	Radial head	3 to 4yr
3	Internal (medial) epicondyle	5 to 6yr
4	Trochlea	7 to 8yr
6	Olecranon	9 to 10yr
1	External (lateral) epicondyle	11 to 12yr